

Effects of Hyperbaric Oxygen Therapy on the Expression of FGF, MMP-9 and Occludin in the Repair of Gastric Mucosal Erosions

by M. Fathi Ilmawan, Soetjipto M. Guritno Suryokusumo, M. Miftahussurur

Submission date: 24-May-2023 02:27PM (UTC+0700)

Submission ID: 2100677004

File name: and_Occludin_in_the_repair_Of_Gastric_Mucosal_Erosions_Fathi.pdf (1.09M)

Word count: 8612

Character count: 47802

Effects of Hyperbaric Oxygen Therapy on the Expression of FGF, MMP-9 and Occludin in the Repair of Gastric Mucosal Erosions

M. Fathi Ilmawan^{1,2}, Soetjipto^{3,*}, M. Guritno Suryokusumo⁴, M. Miftahussurur⁵

M. Fathi Ilmawan^{1,2}, Soetjipto^{3,*},
M. Guritno Suryokusumo⁴, M.
Miftahussurur⁵

¹Doctoral Program of Medical Sciences, Faculty of Medicine, Universitas Airlangga, Surabaya, INDONESIA.

²Department of Internal Medicine, Faculty of Medicine, Universitas Hang Tuah, Surabaya, INDONESIA.

³Universitas Airlangga Hospital, Surabaya; Institute of Tropical Disease, Department of Medical Biochemistry, Faculty of Medicine, Universitas Airlangga, Surabaya, INDONESIA.

⁴Department of Hyperbaric, Universitas Pembangunan Nasional, Jakarta, INDONESIA.

⁵Universitas Airlangga Hospital, Surabaya; Department of Internal Medicine, Faculty of Medicine, Universitas Airlangga, Surabaya, INDONESIA.

Correspondence

Soetjipto

E-mail: soetjipto1950@gmail.com

E-mail: soetjipto1950@gmail.com

History

- Submission Date: 19-04-2022;
- Review completed: 06-05-2022;
- Accepted Date: 09-05-2022.

DOI : 10.5530/pj.2022.14.85

Article Available online

<http://www.phcogj.com/v14/i3>

Copyright

© 2022 Phcogj.Com. This is an open-access article distributed under the terms of the Creative Commons Attribution 4.0 International license.



ABSTRACT

This study was conducted to evaluate the immunohistochemical (IHC) expression of fibroblast growth factor (FGF), matrix metalloproteinase-9 (MMP-9) and occludin in the repair of gastric mucosal erosions in Wistar rats was induced by administration of aspirin, one of the non-steroidal anti-inflammatory drugs (NSAIDs). These expressions are associated with changes in histopathological features. This experimental research used a posttest only control group design. The research sample was 28 male Wistar rats that met inclusion criteria, but not met the exclusion criteria. The samples were randomly allocated into four groups. Group 1 as negative control and group 2 as positive control. Group 3 as treatment 1, which was given HBOT (hyperbaric oxygen therapy) 2.4 ATA for 3 x 30 minutes/day (air break 5 minutes) for 5 days, after aspirin induction at 30 mg/kgBW/day for 10 days. Group 4 as treatment 2, which was given HBOT 2.4 ATA for 3 x 30 minutes/day (air break 5 minutes) for 10 days, after aspirin induction at 30 mg/kgBW/day for 10 days. Each group was evaluated the immunohistochemical (IHC) expression of FGF, MMP-9 and occludin, using the Remmele scale index, immune reactive score (IRS). The expressions were correlated with histopathological changes, using the HAI (Histology Activity Index) method. The results show that the HBOT 2.4 ATA for 3 x 30 minutes/day (air break 5 minutes) for 5 days and for 10 days, it can improve FGF ($p=0.016$) and occludin ($p=0.021$) expression significantly. The HBOT can also reduce inflammation ($p=0.005$), epithelial defects ($p<0.001$) and MMP-9 expression (0.042). There is a significant difference in occludin expression ($p=0.034$) between 5-day HBOT and 10-day HBOT. However, there was no significant difference between the 5-day HBOT and the 10-day HBOT for reduce inflammation ($p=0.845$), epithelial defects ($p=0.469$), FGF expression (0.054) and MMP-9 expression (0.470). The provision of HBOT at 2.4 ATA significantly improved gastric mucosal erosion in NSAID-induced gastric mucosal erosion Wistar rats model, by decreasing MMP-9 expression, as well as increasing FGF and occludin expression. There is a significant difference in occludin expression between 5-day HBOT and 10-day HBOT.

Key words: HBOT, Gastric mucosal erosions, FGF, MMP-9, Occludin.

INTRODUCTION

Erosion of the gastric mucosa and submucosa is a condition of the stomach experiencing inflammation, otherwise known as gastritis. Gastritis is a health disorder that is often found in everyday life. If gastritis is not treated optimally and becoming chronic, gastritis will develop into a peptic ulcer which can lead to bleeding complications, gastric perforation, peritonitis and even death.¹ Indonesia ranks fourth in terms of the number of gastritis cases in the world after China, England, and Bangladesh. Data from the Directorate General of Health, Ministry of Health of the Republic of Indonesia in 2010, gastritis is a disease that is in the fifth position of the top ten inpatient diseases and the sixth position of outpatients in hospitals. The high incidence of gastritis in Indonesia is a problem that needs attention.² The incidence of gastritis in Indonesia is 40.8%, or 274,396 cases of all morbidity.³ The World Health Organization (WHO) world health research agency in 2012, conducted research in several countries in the world and got the results of the percentage of gastritis incidence in the world, including England 22%, China 31%, Japan 14.5%, Canada 35%, and France 29.5%. In the world, the incidence of gastritis is about 1.8 million of the population each year. The incidence of gastritis in Southeast Asia is about 583,635 of the total population each year.

The prevalence of endoscopically confirmed gastritis in the Shanghai population is around 17.2% which is substantially higher than the western population, which is 4.1% and is asymptomatic.⁴

Non-steroidal anti-inflammatory drugs (NSAIDs) are one of the most important causes of gastritis. Other causes of gastritis are infection (*Helicobacter pylori* and cytomegalovirus), stress, diet (low fiber diet, alcohol consumption, and foods that increase stomach acid), and immune compromised patients.¹ Research shows that 52.1% of patients using NSAIDs therapy cause gastric mucosal damage in the form of ulcers.⁵ In other data, it is stated that 70% of patients with long-term NSAIDs therapy, on the endoscopy picture there is mucosal erosion, ulceration, and sub-epithelial bleeding.^{6,7} The use of low-dose aspirin (LDA) is very often prescribed for therapeutic purposes, 5-10% of global/world prescribing.⁸ Based on studies with long-term LDA therapy, it was found that gastroduodenal mucosal damage occurred in 49 patients (51.6%).⁹ The side effects of NSAIDs therapy can be even more severe, namely the occurrence of gastrointestinal bleeding.¹⁰⁻¹³

The therapeutic effect of NSAIDs is to inhibit prostaglandin synthesis. Inhibition of prostaglandin synthesis, via the Cyclooxygenase (COX) enzyme pathway. The role of COX-1 is to secrete mucus and bicarbonate and improve mucosal blood flow. If

Cite this article: Ilmawan MF, Soetjipto, Suryokusumo MG, Miftahussurur M. Effects of Hyperbaric Oxygen Therapy on the Expression of FGF, MMP-9 and Occludin in the Repair of Gastric Mucosal Erosions. *Pharmacogn J.* 2022;14(3): 660-671.

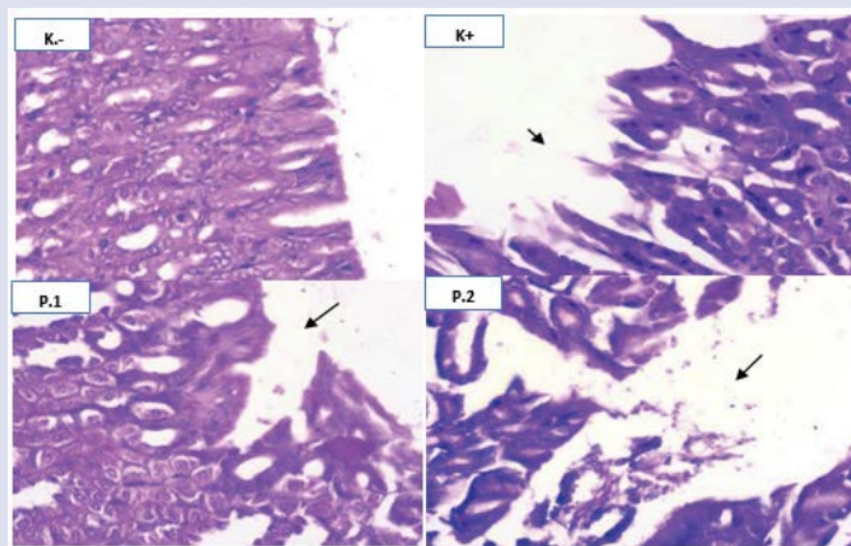


Figure 1: Gastric mucosal epithelium. No mucosal erosion was seen (K-). There was severe erosion of the mucosal epithelium up to the lamina propria. There was mild erosion of the mucosal epithelium (Hematoxylin-eosin staining; Magnification 400x).

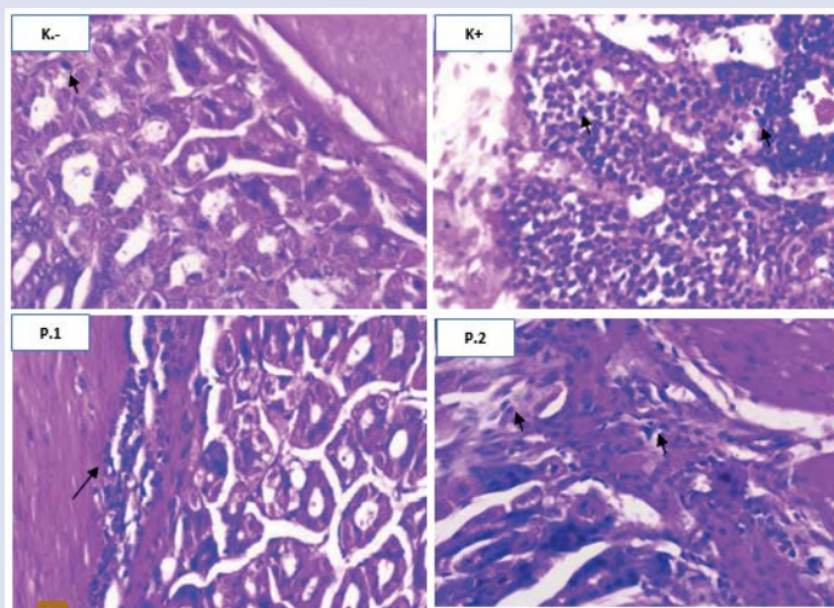


Figure 2: Comparison of the mucosa and submucosa of the stomach. No inflammatory cell infiltration was seen (K-). There was an increase in inflammatory cell infiltration (K+). It appears that the infiltration of inflammatory cells is reduced (P1 dan P2). (▲) showing mononuclear inflammatory cells in the gastric mucosa (Hematoxylin-eosin staining; Magnification 400x).

COX-1 is inhibited it results in tissue ischemia. The role of COX-2 is to improve wound healing and inhibit adherent leukocytes. This leukocyte adhesion resulted in increased levels of neutrophils, Reactive Oxygen Species (ROS) and production of Nitric Oxide (NO).¹⁴⁻¹⁶

The gastric mucosa, which is injured by NSAIDs, can actually heal on its own. This occurs through a complex process and takes 40-150 days for the maturation phase to occur, after wound exposure.¹⁷ The poor healing process can be caused by an increase in the activity of matrix

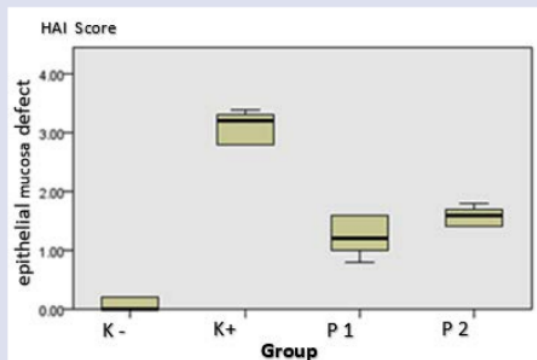


Figure 3: Box plot HAI score epithelial defect in gastric mucosa.

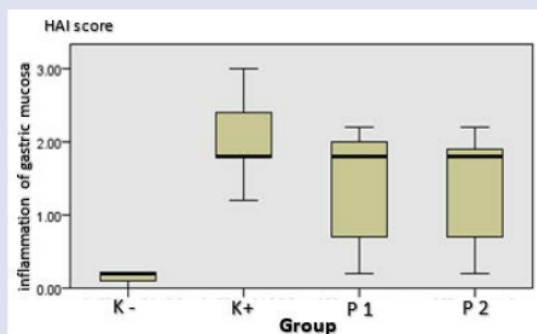


Figure 4: Box plot HAI score inflammation of gastric mucosa.

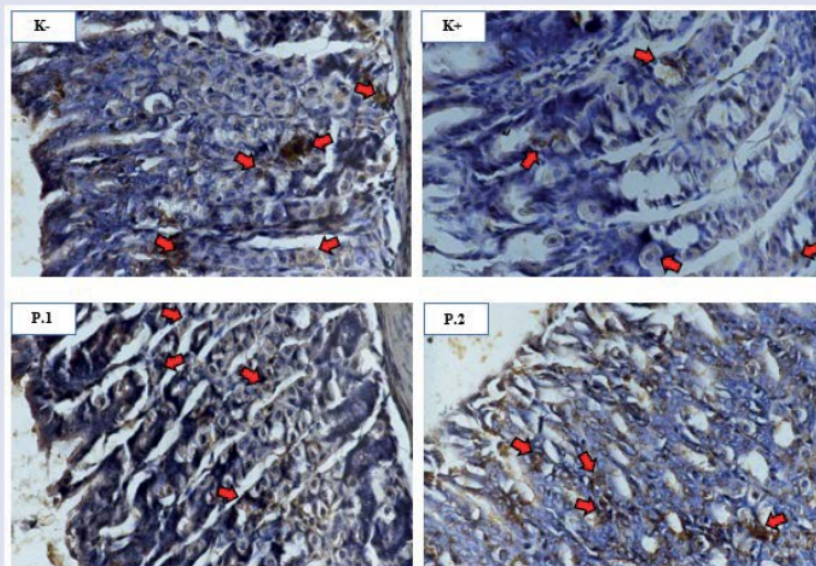


Figure 5: Description of MMP-9 expression in the gastric mucosal layer between groups. Positive expression of MMP-9 in the cell cytoplasm was indicated by the presence of brown color chromogen (arrow) (staining: IHC; magnification: 400x).

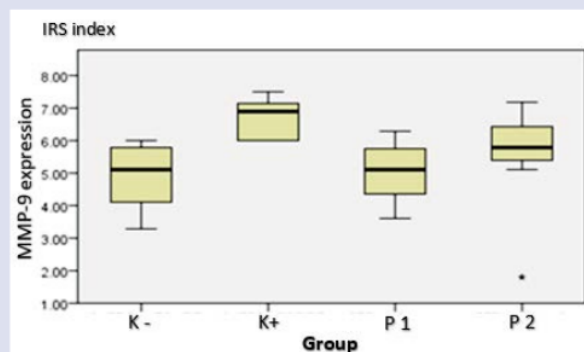


Figure 6: Box plot of MMP-9 expression score on gastric tissue immunohistochemistry examination.

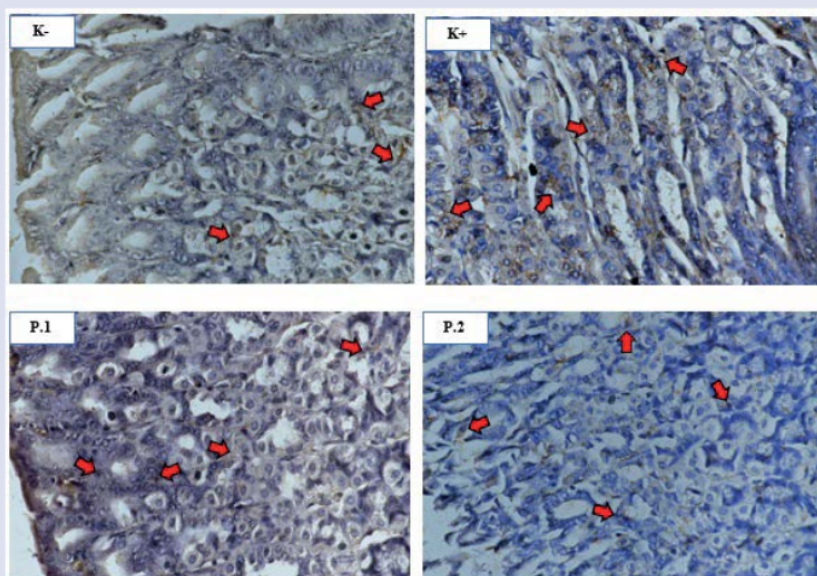


Figure 7: Description of FGF expression in the gastric mucosal layer between groups. Positive FGF expression in cell cytoplasm was indicated by the presence of brown chromogen (arrow) (staining: IHC; magnification: 400x).

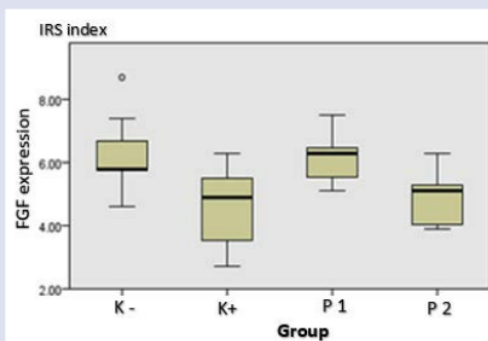


Figure 8: Box plot of FGF expression score on gastric tissue immunohistochemistry examination.

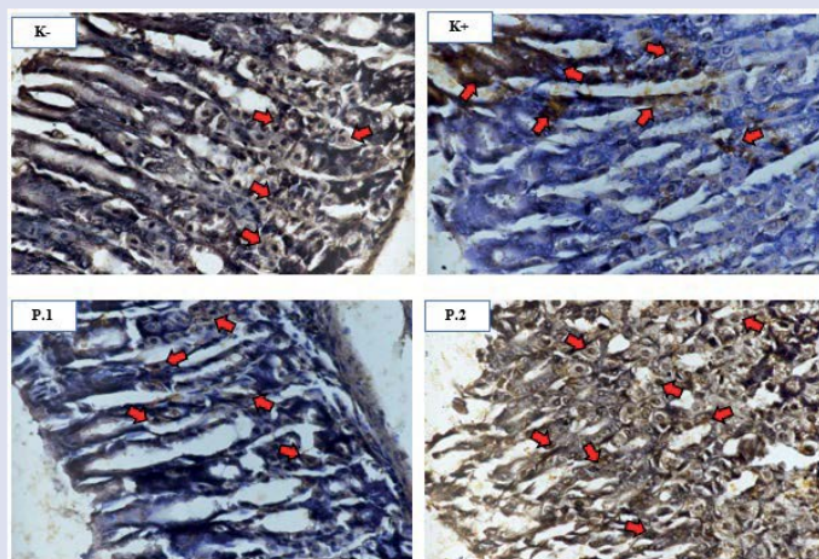


Figure 9: Overview of occludin expression in the gastric mucosal layer between groups. Positive occludin expression in the cytoplasm and cell membranes was indicated by the presence of brown chromogen (arrow) (staining: IHC; magnification: 400x).

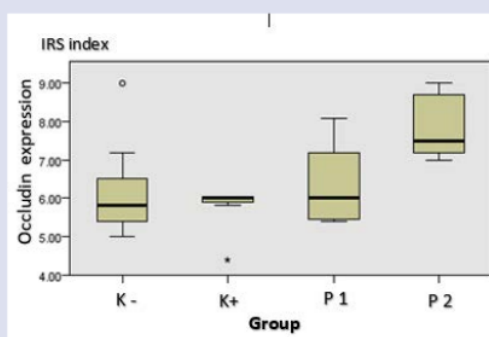


Figure 10: Box plot of occludin expression scores on immunohistochemical examination of gastric tissue.

3 metalloproteinases (MMPs), especially MMP-2 and MMP-9, which contribute to damage to the extracellular matrix (ECM) and basement membrane. MMP-9 activity can be inhibited by tissue inhibitors of metalloproteinase-1 (TIMP-1). TIMP-1 expression occurs 72 hours after MMP-9 degrades the matrix and lyses tissue.^{18,19}

When mucosal erosions or ulcers occur, proinflammatory cytokines activate local fibroblasts, endothelial cells, and epithelial cells. These cells move towards the tissue to differentiate and repair damaged tissue. This is a remodeling process of granulation tissue growth and the generation of new blood vessels through angiogenesis and basic fibroblast growth factor (bFGF), vascular endothelial growth factor (VEGF), platelet derived growth factor (PDGF), transforming growth factor- β (TGF- β) and angiopoietins.^{17,20} 44 roblast growth factor (FGF) belongs to a group of peptides that play an important role in development, homeostasis, and repair processes in several tissues and organ systems, including the gastrointestinal system.^{21,22}

The healing process can also be through increased activity of neutrophil chemotactic factor (NCF). So that there will be cell migration and reepithelization of mucosal erosion. Reepithelization will be stronger in the presence of bonds between epithelial cells by the presence of tight junctions, which function as a barrier to prevent the return of diffusion of acid and pepsin.¹⁷ Tight junctions are plasma membrane proteins, which consist of claudins and occludin. Both have an important role in tight junctions, especially occludin which has a more important role in keeping epithelial cells stable.²³ Occludin has also been shown to be well regulated post-transcriptionally and plays a role in preventing gastrointestinal inflammation.²⁴

Management of gastritis, according to the pathologic that causes it. According to the 2017 American College of Gastroenterology (ACG) and Canadian Association of Gastroenterology (CAG) clinical guidelines, there are several recommended therapies. These therapies are proton pump inhibitors (PPI), prokinetics, tricyclic antidepressants (TCA), psychotherapy and H. pylori eradication.²⁵

Table 1: NF&B expression (scale index using IRS).

MMP-9 expression	Group K(-)	Group K(+)	Group P1	Group P2	p Anova
Mean	5,16	7,83	3,16	5,16	0,042
SD	0,85	0,86	0,54	1,31	
Minimum	3,80	6,60	2,50	2,90	
Maximum	6,00	8,70	4,00	6,70	

Table 2: FGF expression (scale index using IRS).

FGF expression	Group K(-)	Group K(+)	Group P1	Group P2	p Anova
Mean	6,29	4,57	6,13	4,86	0,016
SD	1,34	1,34	0,81	0,89	
Minimum	4,60	2,70	5,10	3,90	
Maximum	8,70	6,30	7,50	6,30	

Table 3: Occludin expression (scale index using IRS).

Occludin expression	Group K(-)	Group K(+)	Group P1	Group P2	p Kruskal-Wallis
Mean	6,24	5,74	6,40	7,90	0,021
SD	1,42	0,96	1,14	0,88	
Minimum	5,00	4,40	5,40	7,00	
Maximum	9,00	6,00	8,10	9,00	

The phenomena mentioned above are the basis for consideration of additional or alternative therapies for gastric mucosal erosions, especially those caused by NSAIDs administration. One such therapy is hyperbaric oxygen therapy (OHB). OHB therapy is carried out through three hypothesis approach, namely: 43 x hypothesis, preconditioning ischemia and hormesis theory.²⁶ The 10th European Consensus Conference on hyperbaric oxygen therapy, made recommendations that hyperbaric oxygen therapy can be given to carbon monoxide poisoning, open fractures, osteoradionecrosis according to level B evidence. There are still some indications for hyperbaric oxygen therapy with level C evidence.²⁷

The main aim of this research was to evaluate the immunohistochemical (IHC) expression of fibroblast growth 17 or (FGF), matrix metalloproteinase-9 (MMP-9) and occludin in the repair of gastric mucosal erosions.¹² Vistar rats was induced by administration of aspirin, one of the non-steroidal anti-inflammatory drugs (NSAIDs). These expressions are associated with changes in histopathological features.

METHODS

This experimental research used a posttest only control group design. The research sample was 28 male Wistar rats that met the inclusion criteria, but not met 5 exclusion criteria. The samples were randomly allocated into four groups. Group 1 as negative control (K-). Group 2 as positive control (K+), NSAIDs induction (aspirin 30 mg/kgBW/day) for 10 days had inflammatory cell infiltration and severe mucosal erosion up to the lamina propria. Group 3 as treatment 1 (P1), which was given HBOT 2.4 ATA for 3 x 30 minutes/day (air break 5 minutes) for 5 days, after aspirin induction at 30 mg/kgBW/day for 10 days. Group 4 as treatment 2 (P2), which was given HBOT 2.4 ATA for 3 x 30 minutes/day (air break 5 minutes) for 10 days, after aspirin induction at 30 mg/kgBW/day for 10 days. Each group was evaluated the immunohistochemical (IHC) expression of FGF, MMP-9 and occludin, using the Remmele scale index, immune reactive score (IRS). The expressions were correlated with histopathological changes, using the HAI (Histology Activity Index) method.

Ethical Requirements: Ethical implications for white rats as experimental animals follow Bioethics Committee of Veterinary Faculty, Airlangga University. Things that need to be carried out according to ethics include the treatment of white rats in a cage, namely one cage one tail, feeding and drinking, air flow into the cage room, treatment during research, taking research analysis units and exterminating them.

Statistical data analysis will be performed using SPSS 23.0. The research data were analyzed using univariate analysis to determine the mean, deviation (SD) minimum value and maximum value. The normality test of data distribution uses the Saphiro-Wilk because the number of n in this study is less than 50. If the data is normally distributed, it meets the parametric requirements, then the ANOVA statistical analysis is used. However, if the distribution is not normal, a non-parametric test is performed with the Kruskal-Wallis test, followed by the Mann-Whitney U post hoc test. In addition, bivariate analysis, one-way ANOVA was used to state the difference in the mean of the variables in the 4 experimental animal groups followed by the Tukey post hoc test (for homogeneous data) and the Games Howell post hoc test (for inhomogeneous data), to determine the difference in mean variables in 2 groups, Multivariate analysis with pathway analysis (path analysis) to determine the significance of the variables according to the existing pathway mechanism. Regression tests were carried out on variables that were suspected to have a strong role (predictors) for other variables.

RESULTS

Effect of OHB 2,4 ATA on gastric mucosal erosion

Histopathological examination of the gastric mucosa was intended to determine the level of damage to the gastric mucosal epithelium of rats and the infiltration of inflammatory cells in the gastric mucosa and submucosa of rats. This histopathological examination was made from tissue samples of 28 Wistar rats. Preparation of preparations and histopathological readings were carried out at the Anatomical Pathology Laboratory, Faculty of Veterinary Medicine, Airlangga University.

The level of damage was assessed based on the HAI (Histology Activity Index) method according to Rogers,²⁸ which was modified with the following criteria: inflammation and epithelial defects. Each criterion has a score range of 0-4 (0=no abnormality; 1 = abnormality < 25%; 2 = 25% - 50% abnormality; 3 = 50% - 75% abnormality; 4 = abnormality >75%). The assessment was carried out based on observations from 5 (five) fields of view of the glandular part of the stomach with 400x magnification. This examination uses an ordinary Nikon E100 light microscope, equipped with a 12 megapixel Optilab Advance Plus digital camera and Image Raste image processing software.

The mean of epithelial defects and gastric mucosal inflammation in the K (+) group had the highest value, while the K(-) group had the lowest value, with an abnormal distribution. The results of the histopathological differences between the treatment groups by Kruskal Wallis analysis were p < 0.001 (in gastric mucosal epithelial defects) and p = 0.005 (in gastric mucosal inflammation). The post hoc test showed that the groups with the most differences in the appearance of inflammation and gastric mucosal epithelial defects were the K (-) and K (+) groups, each p = 0.001. While the P1 and P2 different tests on inflammation and epithelial defects did not experience any difference.

Descriptive and statistical analysis data showed that hyperbaric oxygen therapy (OHB) 2,4 ATA was significant enough to reduce gastric mucosal erosion. This can be seen from the comparison of histopathological examinations in the therapeutic treatment group (P1 and P2) which experienced less inflammation (inflammatory cell infiltration) and lighter erosions compared to the positive control group. Meanwhile, the negative control group, there was no inflammation and erosion of the gastric mucosa.

In the positive control group [K (+)], NSAIDs induction (aspirin 30 mg/kgBW/day) for 10 days had inflammatory cell infiltration and severe mucosal erosion up to the lamina propria. This proves that to make a rat model of gastric mucosal erosion, aspirin can be used for 10 days at a dose of 30 mg/kgBW/day.^{29,30} With this dose it does not cause gastrointestinal bleeding and does not endanger the safety of the experimental animals. The condition of the K (+) group rats before termination still looked healthy and active.

Induction with NSAIDs can't simply cause erosion of the gastric mucosa, because the stomach also has a defensive factor to protect against erosion. These defensive factors are the production of bicarbonate in the mucosa and prostaglandins in the microcirculation. Under normal circumstances, defensive factors can compensate for aggressive factors by maintaining a good diameter of the capillary lumen so that the supply of oxygen and food juices remains smooth so that acid cannot be penetrated and there is no damage. Balance disorders, with aggressive factors being more dominant than defensive factors can cause erosion of the gastric mucosa.³¹

Several other endogenous mediators that can play a role in protecting the gastric mucosa are nitric oxide (NO) and Lipoxin. According to Wallace, the defense factor (defensive) of the gastric mucosa consists of several components that form a complex network. The complex network is: 1) extramucosal components, namely acid, mucus, phospholipids, and bicarbonate; 2) Epithelium; 3) microcirculation; 4) mucosal immune system; 5) the ability of the mucosa to repair.^{32,33}

Administration of NSAIDs has the effect of inhibiting the synthesis of prostaglandins, whereas prostaglandins play an important role in protecting the gastric mucosa. Inhibition of prostaglandin synthesis results in changes in gastric and duodenal microcirculation, via the Cyclooxygenase (COX) enzyme inhibitory pathway. The role of COX-1 is to secrete mucus and bicarbonate and improve mucosal blood flow, while COX-2 has a role to improve wound healing and inhibit adherent leukocytes. One of the NSAIDs that is often consumed is aspirin, which works by inhibiting COX-1 and COX-2.^{16,34}

Aspirin therapy inhibits prostaglandin synthesis, via the Cyclooxygenase (COX) enzyme pathway. If COX-1 is inhibited there will be a decrease in blood flow resulting in tissue ischemia. If COX-2 is inhibited it will interfere with wound healing and increase adherent leukocytes. This leukocyte adhesion resulted in increased levels of neutrophils, Reactive Oxygen Species (ROS) and production of Nitric Oxide (NO). The end result of inhibition of COX-1 and COX-2, will result in injury and ulceration of the gastric mucosa.¹⁴⁻¹⁶

The treatment groups (P1 and P2) were subjected to the same induction as the K(+) group, followed by 5 days of OHB therapy for P1 group and 10 days of OHB therapy for P2 group. From the results of histopathological examination, it appears that the infiltration of inflammatory cells and mucosal erosions were lighter in the treatment group (P1 and P2) compared to that in the K(+) group. This difference is quite significant when viewed from the reduction in mucosal erosion that occurs, whereas when viewed from the infiltration of inflammatory cells this difference is not significant.

The difference in repair of mucosal epithelial erosion that occurred in the P1 and P2 groups was not significant. This shows that OHB therapy for 5 days is sufficient to repair mucosal epithelial damage. Whereas in general the wound healing process is very complex, takes a short time and includes the following steps: hemostasis, inflammation, proliferation/granulation and remodeling phases. Each phase has a certain period of time: 1-3 days, 3-20 days, 7-40 days and 40 days up to 2 years.^{17,35} This study shows that OHB therapy can accelerate the wound healing process, especially in the inflammatory and proliferative phases.

Identical results were obtained in the hyperbaric oxygen therapy study²¹ Wistar rats injured 1x1 cm. The treatment group was divided into 2 groups, the first group was given OHB therapy for 5 days and the second group was given OHB therapy for 10 days. Each treatment group has a control group. Wound healing in the group given OHB therapy for 5 days was significantly different from the control group. Meanwhile, the treatment group with OHB therapy for 10 days was different but not significant when compared to the control group.³⁶

OHB therapy in gastric mucosal erosion caused by NSAIDs is in accordance with the pathological that occurs. Aspirin therapy inhibits prostaglandin synthesis, via the COX enzyme pathway, which results in tissue ischemia and ROS activation. While the OHB therapy approach is the redox hypothesis (oxidative stress), ischemia (lack of oxygen in the tissues) and the hormesis theory (change in exposure from low doses that are protective, to dangerous when exposed to higher doses).³⁶ So, this OHB therapy can be given to gastric mucosal erosions caused by NSAIDs.

OHB therapy is good enough to improve the condition of tissue ischemia. Oxygen in the blood is transported in a soluble form in plasma fluids and forms bonds with hemoglobin (97%). and only a small fraction is soluble in plasma (3%). In OHB therapy, this dissolved oxygen becomes important because it is more easily consumed by tissues through direct diffusion than oxygen bound to hemoglobin.³⁶ At normal ambient air pressure, only a small amount of oxygen dissolves in the blood. But in hyperbaric conditions, it allows an increase in the solubility of oxygen, which is sufficient to meet the body's oxygen needs, because oxygen dissolved in plasma is utilized much faster than that bound in hemoglobin (oxyhemoglobin).³⁷

The oxygen needed by the body comes from the outside air and to get into the cells it must pass through the pulmonary capillary system, then pass through the interstitial and intercellular fluids and finally enter the cellular system. Oxygen in cells enters the utilization process in peroxisomes, endoplasmic reticulum, and mitochondria. The use of oxygen mainly occurs in the mitochondria, which is about 80% while 20% is used by other sub-cellular, such as microsomes, nucleus, plasma membrane and others. Under normal conditions, the rate at which oxygen is used is determined by the rate at which ADP and ATP are generated. The diffusion distance from the wall to the cell is about 50 mm and usually oxygen can reach the cell quickly. If pO₂ falls below a critical pressure of 1-3 mmHg, then oxygen utilization in cells depends on diffusion and not on ADP. The process of entering oxygen in the body to its utilization by cells, goes through several stages (phases): Ventilation Phase, Transport Phase, Utilization Phase, and Diffusion Phase.³⁸

Research on OHB therapy for 7 days has also been carried out on colitis rats. In this study, it was found that histopathological colitis model rats experienced milder inflammation than the colitis model rats without OHB therapy. This study found a decrease in neutrophil and monocyte infiltration, and a decrease in inflammatory mediators (interleukin-6 / IL-6) as well as an increase in the antioxidant enzyme glutathione peroxidase1 (GPx1).³⁹

OHB therapy, apart from being tested on experimental animals, has also been used in gastrointestinal diseases, such as IBD. There were 13 studies on Crohn's disease and 6 studies on ulcerative colitis. Based on the analysis and systematic review, it was concluded that OHB therapy improved the symptoms and signs of IBD, by reducing the concentration of pro-inflammatory cytokines, reducing inflammatory biomarkers and oxidative stress, with minimal side effects.⁴⁰

In a case of gastritis, it was reported that there was a 68-year-old male patient who had bleeding for 4-5 weeks after esophagectomy surgery. The results of the endoscopic examination showed the presence of

bleeding. The patient refused gastrectomy, and was given alternative therapy with OHB 3x30 minutes/cycle. Three days of OHB therapy, melena stopped, and 2 weeks later had a re-endoscopy, the gastritis and bleeding were improved.⁴¹

Another study used combination therapy of rebamipide and pantoprazole in patients undergoing endoscopic gastric submucosal dissection. The results showed that the ulcer healing rate occurred at week 4, after dissection.⁴² Shorter therapeutic procedure time was an independent predictive factor for a high ulcer healing rate. However, it cannot be concluded that the combination therapy is inferior to OHB therapy. So, someday it is necessary to conduct a study to compare the combination therapy with OHB therapy.

The studies and cases above underlie that OHB therapy improves tissue ischemia and suppresses oxidative stress due to NSAIDs administration so that it can improve inflammation and mucosal erosion in the gastrointestinal tract. OHB therapy can also accelerate wound healing, especially in the inflammatory and proliferative phases. So with a faster recovery, complaints and symptoms are reduced more quickly.

Effect of OHB 2,4 ATA on MMP-9 expression

Examination of MMP-9 expression is an immunohistochemical examination, to determine the expression of MMP-9 in the gastric mucosal layer. The data for each sample was assessed semi-quantitatively according to the modified Remmele (Immunoreactive Score/IRS) method.⁴³ The IRS semiquantitative scale is the result of multiplying the percentage score of positive cells (A) with the color reaction intensity score (B), so $IRS = (A \times B)$. Score at group A: 0 = no positive; 1 = positive cell less than 10%; 2 = positive cell 11% - 50%; 3 = positive cell 51% - 80%; 4 = positive cell more than 80%. Score at group B: 0 = no color reaction; 1 = weak color intensity; 2 = medium color intensity; 3 = strong color intensity.

Descriptive and statistical analysis data showed that hyperbaric oxygen therapy (OHB) 2,4 ATA significantly reduced MMP-9 expression. MMP-9 expression in the treatment group (P1), decreased significantly when compared to the positive control group and the negative control group. However, in the P2 group, the expression of MMP-9 increased when compared to P1. Perhaps this indicates that 5 days of OHB therapy has been able to reduce MMP-9, which in turn accelerates healing of mucosal erosion. Identical to the results of the expression of IL-8 and IL-10, in the expression of MMP-9 after healing has been achieved, the activity of MMP-9 expression decreases towards a stable direction.

The mean in the K (+) group has the highest value while the K (-) group has the lowest value. The distribution of MMP-9 expression based on the Shapiro-Wilk test was normally distributed. Levene's test to test the homogeneity of MMP-9 expression obtained p value based on mean > 0.05, meaning that the data is homogeneous so that the statistical test that can be used is Anova, followed by post hoc test using Tukey. Based on the Tukey test, the value of p = 0.042. These results indicate that there are significant differences in MMP-9 expression between the treatment groups.

The results of this study showed that the expression of MMP-9 in the aspirin-induced K (+) group increased when compared to the K (-) group that was not induced by aspirin. Gastric mucosal epithelium erosions or wounds due to NSAIDs, can actually heal on its own. This occurs through a complex process and takes 40-150 days for the maturation phase to occur, after wound exposure.¹⁷ The poor healing process can be caused by an increase in the activity of matrix metalloproteinases (MMPs), especially MMP-2 and MMP-9, which contribute to damage to the extracellular matrix (ECM) and basement membrane. MMP-9 activity can be inhibited by tissue inhibitors of metalloproteinase-1 (TIMP-1). TIMP-1 expression occurs 72 hours after MMP-9 degrades the matrix and lyses tissue.^{18,19}

OHB therapy in gastric mucosal erosion caused by NSAIDs is in accordance with the pathological that occurs. Tissue ischemia and ROS activation are reduced. The healing process went well, one of which was marked by a decrease in MMP-9 expression. Matrix metalloproteinase-9 (MMP-9) is one of the gelatinases that degrade type-IV collagen, also a component of cell basement membranes. Besides being expressed in the digestive tract, MMP-9 together with MMP-2, will increase its expression in cases of ovarian cancer, inflammatory diseases (e.g., esophagitis) and some complications of diabetes mellitus.⁴⁵ Increased activity of matrix metalloproteinases (MMPs), especially MMP-2 and MMP-9, results in poor healing processes in injury or inflammation.¹⁹

Research on the effect of giving OHB to decrease MMP-9 expression in gastrointestinal organs is still limited. Research on the effect of OHB therapy on decreasing MMP-9 expression in other organs, including in cases of brain metastases and cases of diabetic wound healing in experimental animals. The results of these two studies prove that OHB therapy can reduce MMP-9 expression and improve the situation in each of these cases.^{45,46}

MMP-9 expression in the P2 group, had a lower value than the P1 group. This can occur, related to the healing process which includes several phases: hemostasis, inflammation, proliferation/granulation, remodeling. When the gastric mucosa is induced by aspirin, the expression of MMP-9 will increase. Furthermore, the expression of MMP-9 will rapidly decrease after receiving OHB therapy for 5 days, and will return to normal, despite being treated with OHB for 10 days.

MMP-9 expression increased gastric mucosal erosion ($p = 0.000$; = 0.795), so there was a very significant positive correlation. When the gastric mucosa is induced by aspirin, the expression of MMP-9 will increase, and mucosal damage will increase when the healing process went well, it was marked by a decrease in MMP-9 expression. MMP-9 expression can actually be inhibited by tissue inhibitors of metalloproteinase-1 (TIMP-1). TIMP-1 expression occurs 72 hours after MMP-9 degrades the matrix and lyses tissue.¹⁹

Effect of OHB 2,4 ATA on FGF expression

Examination of FGF expression is an immunohistochemical examination, to determine the expression of FGF in the gastric mucosal layer. The data for each sample was assessed semi-quantitatively according to the modified Remmele (Immunoreactive Score/IRS) method, same with examination of MMP-9 expression.

From the descriptive and statistical analysis data, it appears that hyperbaric oxygen therapy (OHB) 2,4 ATA is significant enough to increase FGF expression. FGF expression in the treatment group (P1), increased significantly when compared to the positive control group and the negative control group. In the P2 group the mean FGF expression was lower than the P1 group. Perhaps this indicates that OHB therapy for 5 days has been able to increase the expression of FGF and subsequently can improve inflammation.

The phenomenon that the expression of FGF in the P2 group was lower than in the P1 group could also be influenced by the healing phase. Initially, there is an epidermal growth factor (EGF) response, the activity is quite short, which reacts after injury (30 minutes-2 hours). Furthermore, there is an intermediate response, namely the growth of granulation tissue and the generation of new blood vessels through angiogenesis and growth factors [basic fibroblast growth factor (bFGF), vascular endothelial growth factor (VEGF), platelet derived growth factor (PDGF), transforming growth factor- β (TGF- β) and angiotensins (6hours-2 days)]. In the next response for 14 days.^{17,20}

In this study, the expression of FGF in the aspirin-induced K (+) group decreased when compared to the K (-) group that was not induced by aspirin. This can be caused by damage or interference with the gastric

mucosal defensive factors. Meanwhile, FGF is a defensive factor found in the subepithelial layer.

Gastrointestinal mucosal defensive factors can be divided into 3 parts: pre-epithelial, epithelial, and subepithelial. Each section consists of the following components: (1) Pre-epithelial : (i) Mucus layer = hydrophobic barrier, mucus composition, trefoil peptide, and mucus thickness regulation; (ii) mucus layer pH = lumen pH and pH balance; (iii) Lumen contents = nutrients and gastric acid; (2) Epithelial: (i) Mucosal permeability = Apical membrane and Intercellular Junctions (ii) Regulation of pH = acid-base balance; (iii) Hormonal regulation = melatonin, leptin, estrogen, thyrotropin releasing hormone (TRH), amylin and endorphins. (iv) Antioxidant compounds = nitroguanine; (v) Stress protein induced by mucosal injury = MMP, survivin, heat shock prot-16 (HSP), annexin, and heme Oxygenase-1. (3) Subepithelial: (i) Growth factor = vascular endothelial growth factor (VEGF), basic fibroblast growth factor (bFGF), platelet derived growth factor (PDGF); (2) Mucosal blood flow, controlled by the central and enteric nervous systems; (iii) Submucosal elements = acid sensor, neural effects, chemical mediators (iv) Gastric protective receptors = E-type prostaglandin (EP), angiotensin (AT) receptor, peroxisome proliferator activated receptor- γ (PPAR).

OHB therapy in gastric mucosal erosion caused by NSAIDs is in accordance with the pathological that occurs. Induction of aspirin inhibits prostaglandin synthesis, via the COX enzyme pathway, resulting in tissue ischemia and ROS activation. In addition, NSAID therapy can cause topical irritation, which in turn causes damage to the epithelium. Several markers that can be affected are tight junction, MMP-9 and FGF.⁴⁷ Among them are as follows: 1. Treatment of ocular herpes, can use FGF-1 therapy, through the mechanism of increasing anti-inflammatory M2. One of the anti-inflammatory M2 is IL-10.⁴⁸ 2. Another study used the expression of FGF-21 which can ameliorate the inflammation induced by lipopolysaccharide (LPS), by increasing the expression of IL-10.⁴⁹

Another pathway analysis showed that FGF expression increased occludin expression so it was significantly positively correlated. Epithelial-mesenchymal transition (EMT) is an important process that plays key physiological and pathological roles, such as embryogenesis, wound healing, and cancer development. The collaboration of EMT and FGF will increase the adhesion of molecules, which will strengthen tight junctions, including occludin and claudin.⁵⁰

At the beginning of the healing phase, an epidermal growth factor (EGF) response occurs, its activity is quite short, which reacts after injury (30 minutes-2 hours). Furthermore, there is an intermediate response, namely the growth of granulation tissue and the generation of new blood vessels through angiogenesis and growth factors [basic fibroblast growth factor (bFGF), vascular endothelial growth factor (VEGF), platelet derived growth factor (PDGF), transforming growth factor- β (TGF- β) and angiotensins]. (6hours-2 days). In the next response for 14 days.^{17,20}

The healing process, as above, can explain why on OHB therapy in group P2 (10 days of OHB therapy). FGF expression was lower than in P1 group (5 days of OHB therapy). FGF expression will rapidly increase after receiving OHB therapy for 5 days, and will decrease back to normal, even though OHB therapy is continued for 10 days. This will be inversely proportional to the expression of MMP-9. The phenomenon that emerges is the correlation which is like a mirror image. We can see this phenomenon in the box plot diagram for each of these variables.

There are several studies that prove that OHB therapy increases FGF expression. OHB therapy can improve calvaria defects, with increased FGF expression, although the increase in FGF was not statistically significant.⁵¹ FGF expression increased significantly after OHB

therapy in cases of peripheral arterial occlusive disease (PAOD).⁵² FGF expression also increased significantly after being given OHB therapy, especially in the first 3-7 days, in cases of muscle contusion.⁵³

Effect of OHB 2,4 ATA on occludin expression

Examination of occludin expression is an immunohistochemical examination, to determine the expression of occludin in the gastric mucosal layer. The data for each sample was assessed semi-quantitatively according to the modified Remmele (Immune Reactive Score/IRS) method, same with examination of MMP-9 expression.

The descriptive and statistical analysis data, it appears that hyperbaric oxygen therapy (OHB) 2,4 ATA is significant enough to increase occludin expression. The expression of occludin in the treatment group (P2), increased significantly if the positive control group and negative control group were walled off. As for the P1 group, the increase in occludin expression was not significant.

Occludin is part of the tight junction, which is in the gastric epithelium. Occludin is part of the defensive factors of the gastric mucosa.⁴⁷ Tight junctions are plasma membrane proteins that are important as shields in the gastrointestinal tract, consisting of claudins and occludin. Both have important roles in tight junctions (TJs), especially occludin, which was the first TJ discovered and has a more important role in keeping epithelial cells stable.^{23,54} In addition to being one of the keys to maintaining the integrity of the digestive tract epithelium, occludin has also been shown to be a good post-transcriptional regulator and also plays a role in preventing gastrointestinal inflammation.²⁴ Occludin also acts as a barrier to maintain the integrity of the TJ against oxidation-reduction and interacts strongly with zonular occludens-1 (ZO-1), which is attached to the cytoskeleton structure.⁵⁵

Pathway analysis showed that occludin expression was stimulated by FGF expression and inhibited gastric mucosal erosion. The correlation between FGF and occludin has been described previously. There are several studies that show the role of occludin in the digestive tract. Research by Liu *et al.* (2018), proved that giving mosapride protects experimental animals from gastric injury after aspirin induction, by increasing occludin expression. So that the occurrence of gastric mucosal erosion can be prevented.¹⁹ In the case of inflammatory bowel disease (IBD), downregulation occludin suppresses caspase-3 expression to limit excessive apoptosis, so that mucosal damage in IBD can be suppressed.⁵⁴

Research on the effect of giving OHB on occludin expression in gastrointestinal organs is still limited. Research on colitis model rats given OHB therapy on histopathologic features experienced milder inflammation. One of the mechanisms is the activity of antioxidant enzymes that make TJ stronger.³⁹ HBO therapy significantly improves neurologic function, reduces intestinal mucosal injury, maintains intestinal barrier integrity and increases occludin expression through spinal cord injury (SCI). HBO therapy significantly inhibited the Rho/ROCK (Ras homologous/Rho-associated coiled-coil forming protein kinase) pathway, which is the basic mechanism of TJ regulation due to HBO therapy.⁵⁶

CONCLUSION

The provision of HBOT at 2.4 ATA significantly improved gastric mucosal erosion in NSAID-induced gastric mucosal erosion Wistar rats model, by decreasing MMP-9 expression, as well as increasing FGF and occludin expression. There is a significant difference in occludin expression between 5-day HBOT and 10-day HBOT.

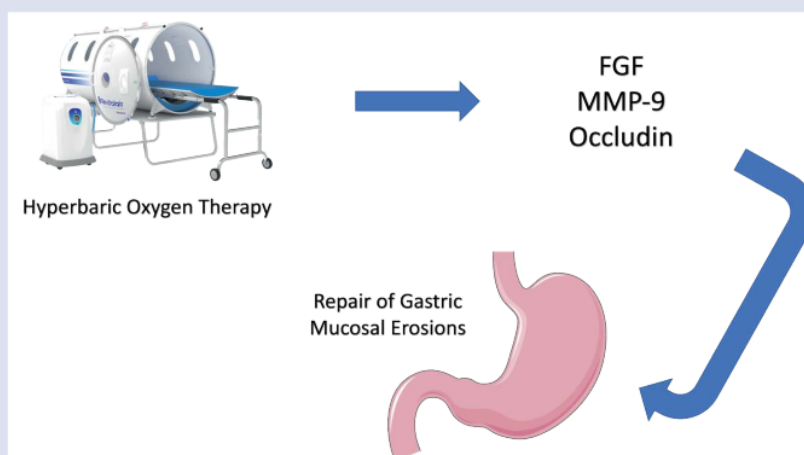
REFERENCES

- Hirlan. Gastritis. In I. A. Siti Setiati, Buku Ajar Ilmu Penyakit Dalam. Jakarta: Internal Publishing. 2017;1770-1773.

2. KEMENKES. In Profil Kesehatan Indonesia 2010. Jakarta: Ministry of Health, Republic of Indonesia. 2013.
3. Novitasary A, Sabilu Y, Ismail CS. Faktor Determinan Gastritis Klinis pada Mahasiswa di Fakultas Kesehatan Masyarakat Universitas Halo Oleo tahun 2016. Jurnal Ilmiah Mahasiswa Kesehatan Masyarakat, 2017;2: 1-10.
4. Tamasse IF. Analisis Gambaran Histopatologi Mukosa Lambung dan Bakteri *Helicobacter pylori* Pada Pasien Gastritis DI RSUP Dr. Wahidin Sudirohusodo Tahun 2016. 2017.
5. Surya DS, Arsin AA, Ansar J. Faktor yang berhubungan dengan kejadian gastritis di Puskesmas Biru Kabupaten Bone. Hasanuddin Journal of Public Health. 2020;1(2):172-182.
6. Foong WD, McAlindon ME. Non-steroidal anti-inflammatory drugs and the gastrointestinal tract. Clinical Medicine Gastroenterology. 2021;21(2):131-134.
7. Seo SI, Kang JG, Kim HS, Shin WG, Jang MK, Lee JH, *et al.* Risk of peptic ulcer bleeding associated with *helicobacter pylori* infection, nonsteroidal anti-inflammatory drugs, and low-dose aspirin therapy in peptic ulcer disease: A case-control study. The Korean Journal of *helicobacter* and upper gastrointestinal. 2019;19:42-47.
8. McEvoy L, Carr DF, Pirmohamed M. Pharmacogenomics of NSAID-induced Upper Gastrointestinal Toxicity. Frontier in Pharmacology. 2021;12:1-11.
9. Ari F, Syam AF, Makmun D, Suhendro. Gastroduodenal mucosal Injury Profile in Long-term Low-dose Aspirin Users and Its Influencing Factors. The Indonesian Journal of Gastroenterology, Hepatology and Digestive Endoscopy. 2016;162-169.
10. Jui Luo P, Lin XH, Lin CC, Luo JC, Hu HY, Ting PH, *et al.* Risk factors for upper gastrointestinal bleeding among aspirin users: An old issues with new findings from a population-based cohort study. Journal of the Formosan Medical Association. 2019;118(5):938-944.
11. Nagata N, Niikura R, Yamada A, Sakurai T, Shimbo T, Kobayasi Y, *et al.* Acute middle Gastrointestinal Bleeding risk associated with NSAIDs, Antithrombotic Drugs, and PPIs: A Multicenter Case-Control Study. Journal Pone. 2016;11(3):e0151332.
12. Petersen J, Hansen JM, Muckadell, Dall M, Hallas J. A model to predict the risk of aspirin/non steroidal anti-inflammatory drugs-related upper gastrointestinal bleeding for the individual patient. Nordic association for the publication of BCPT. 2019;437-444.
13. Rodriguez LG, Peres MP, Hennekens CH, Rothwell, Lanas A. Bleeding risk with long-term Low-dose aspirin: A Systematic Review of Observational studies. Journal pone. 2016;11(8):e0160046.
14. Lavie CJ, Howden CW, Scheiman J, Tursi J. Upper Gastrointestinal toxicity associated with Long Term Aspirin therapy: Consequences and Prevention. Curr Probl Cardiol. 2017;42(5):146-164.
15. Wallace JL, Fiorucci S. A magic bullet for mucosal protection and aspirin is the trigger. TRENDS in Pharmacological Sciences. 2003;24(7):323-326.
16. Wallace JL, Vong L. NSAID-induced gastrointestinal damage and the design of GI-sparing NSAIDs. Current opinion in Investigational Drugs. 2008;9(11):151-156.
17. Fomai M, Antonioli L, Colucci R, Tuccori M, Blandizzi C. Pathophysiology of gastric ulcer development and healing: Molecular mechanism and novel therapeutic options. 2011;113-142.
18. Ganguly K, Swarnakar S. Induction of matrix metalloproteinase-9 and -3 in nonsteroidal anti-inflammatory drug-induced acute gastric ulcers in mice : regulation by melatonin. Journal of Pineal Research. 2009;47(1):43-55.
19. Liu N, Huang J, Sun S, Zou Z, Zhang J, Gao F, *et al.* Expression of matrix metalloproteinase-9, cyclooxygenase-2 and vascular endothelial growth factor are increased in gastrointestinal stromal tumors. International journal Clin Med. 2015;8(4):6495-501.
20. Li SL, Zhao JR, Ren XY, Jia-Ping Xie. Increased Expression of matrix metalloproteinase-9 associated with gastric ulcer recurrence. World Journal of Gastroenterology. 2013;19(28):4590-4595.
21. Donopoulou S, Schlieve CR, Grikscheit TC, Alam DA. Fibroblast Growth factors in the gastrointestinal Tract: Twists and Turns. Developmental Dynamics. 2017;246(4):344-352.
22. Prudovsky I. Cellular Mechanisms of FGF-Stimulated Tissue Repair. Cells-MDPI. 2021;10(7):1830.
23. Lee B, Moon KM, Kim CY. Tight Junction in the Intestinal Epithelium : Its Association with Diseases and Regulation by Phytochemicals. Journal of Immunology Research. 2018;2018:2645465.
24. Singh V, Gowda CP, Singh V, Ganapathy AS, Karamchandani DM, Eshelman MA, *et al.* The mRNA-protein binding protein IGF2BP1 maintains intestinal barrier function by up-regulating occludin expression. Journal Biology-Chemistry. 2020;295(25):8602-8612.
25. Moayyedi PM, Lacy BE, Adreus CN, Enns RA, Howden CW, Vakili N. ACG and CAG Clinical Guideline: Management of Dyspepsia. The American Journal of Gastroenterology. 2017;112(7):988-1013.
26. Suryokusumo MG. Hyperbaric Medicine and Hyperbaric Facility. Jakarta: FK UI. 2015.
27. Mathieu D, Marroni A, Kot J. Tenth European Consensus Conference on Hyperbaric Medicine: recommendations for accepted and non-accepted clinical indications and practice of hyperbaric oxygen treatment. Diving and Hyperbaric Medicine. 2017;47(2):24-32.
28. Rogers AB. Histologic Scoring of Gastritis and Gastric Cancer in Mouse Models. Methods in Molecular Biology. 2012;921:189-203.
29. Nanlohy VJ, Kairupan C, Loho L. Gambaran histopatologi Lambung Tikus Wistar yang diberikan buah pepaya sebelum induksi aspirin. Jurnal e-Biomedik (eBM). 2013;1:972-976.
30. Sundalangi CF, Loho L, Kairupan C. Gambaran histopatologi lambung tikus Wistar yang diberikan ekstrak daun sirsak *Annona muricata* L) setelah induksi aspirin. Jurnal e-Biomedik. 2006.
31. Kaunitz JD, Akiba Y. Gastroduodenal mucosal defense : Role of endogenous mediators. CCurr Opin Gastroenterology. 2004;20(6):526-532.
32. Wallace JL, Lima OM, Fiorucci S. Lipoxins in Gastric. Prostaglandins, Leukotriens and Essential Fatty Acids. 2005;73:251-255.
33. Martin GR, Wallace JL. Gastrointestinal Inflammation: A Central Component of Mucosal Defense and Repair. Calgary-Canada: The Society for Experimental Biology and Medicine. 2006;231(2):130-137.
34. Takeuchi K. Pathogenesis of NSAID-induced gastric damage: importance of cyclooxygenase inhibition and gastric hypermotility. World Journal of Gastroenterology. 2012;18(18):2147-2160.
35. Husen SA, Syadzha MF, Setyawan MF, Pudjiastuti P, Ansori ANM, Susilo RJK, *et al.* Evaluation of the Combination of *Sargassum duplicatum*, *Sargassum ilicifolium*, *Abelmoschus esculentus*, and *Garcinia mangostana* Extracts for Open Wound Healing in Diabetic Mice. Systematic Reviews in Pharmacy. 2020;11(9):888-892.
36. Winarni D, Husna FN, Syadzha MF, Susilo RJK, Hayaza S, Ansori ANM, *et al.* Topical Administration Effect of *Sargassum duplicatum* and *Garcinia mangostana* Extracts Combination on Open Wound Healing Process in Diabetic Mice. Scientifica. 2022;2022:9700794.
37. Mathieu D. Handbook on Hyperbaric Medicine. Statewide Agricultural Land Use Baseline 2015 (Vol. 1). Netherlands: Springer. 2006.
38. Mahdi H, Sasongko, Siswanto, Hinarya D, Supriyoto, Susanto A. Buku Ajar Ilmu Kesehatan Penyelam dan Hiperbarik. Jakarta. 2013.
39. Novak S, Drenjancevic I, Vukovic R, Kellermayer Z, Cosic A, Levak MT, *et al.* Anti-inflammatory Effects of Hyperbaric Oxygenation during DSS-Induced Colitis in BALB/c mice Include Change in Gen Expression of HIF-1alfa, Proinflammatory Cytokines, and Antioxidative Enzyme. Mediators of Inflammation. 2016;2016:7141430.

40. Rossignol DA. Hyperbaric oxygen treatment for inflammatory bowel disease: a systematic review and analysis. *Medical gas research*. 2012;1-11.
41. Kernstine KH, Greensmith JE, Johlin FC, Funk GF, De Armond DT, Natta TVL, *et al.* Hyperbaric oxygen treatment of hemorrhagic radiation-induced gastritis after esophagectomy. *The Society Thoracic Surgeons*. 2005;80(3):1115-1117.
42. Jung DH, MD Park JC, Lee YC, Lee SK, MD Shin SK, Chung H, *et al.* Comparison of the Efficacy of Polaprezinc Plus Proton Pump Inhibitor and Rebamipide Plus Proton Pump Inhibitor Treatments for Endoscopic Submucosal Dissection-induced Ulcers. *Clin Journal gastroenterol*. 2021;55(3):233-238.
43. Novak M, Madej JA, Dziegieil P. Intensity of Cox 2 expression in Cell of Soft Tissue Fibrosarcomas in Dog As Related to Grade of Tumor malignation. *Bull Vet inst Pulawy*. 2007;51:275-279
44. Montiel-Jarquín AJ, Cisneros LGV, Colombo LA, Mendoza SHA, Marquez PML, Figueroa RMS. Expression of metalloproteinase-9 in patients with mild and severe forms of gastroesophageal reflux disease. *Cir-cir*. 2019;87(4):436-442.
45. Tao J, Gao Z, HUANG R, Li H. Therapeutic effect of combined hyperbaric oxygen and radiation therapy for single brain metastasis and its influence on osteopontin and MMP-9. *Eksperimental and therapeutic medicine*. 2019;465-471.
46. Fadholly A, Ansori AN, Proboningrat A, Kusala MK, Putri N, Pertiwi VR, *et al.* An investigation on the *Euphoria longan* (Lour.) Steud seeds in wound healing in *Rattus norvegicus*. *Indian Veterinary Journal*. 2020;97(2):26-29.
47. Ham M, Akiba Y, Takeuchi K, Montrose MH, Kaunitz JD. Gastroduodenal Mucosal Defense. In L. R. Johnson, *Physiology of The Gastrointestinal Tract*. Oxford: Academic Press. 2012;1169-1208.
48. Dhanushkodi NR, Srivastava R, Coulon PG, Rakash S, Roy S, Bagnol D, *et al.* Healing of ocular herpetic disease following treatment with an engineered FGF-1 is associated with increases corneal anti-inflammatory M2 macrophages. *Frontiers of immunology*. 2021;12:1-12.
49. Li JY, Wang N, Khoso NH, Shen CB, Guo MZ, Pang X, *et al.* FGF-21 Elevated IL-10 Production to Correct LPS-Induced Inflammation. *Inflammation*. 2018;41(3):751-759.
50. Husen SA, Setyawan MF, Syadzha MF, Susilo RJ, Hayaza S, Ansori AN, *et al.* A novel therapeutic effects of *Sargassum ilicifolium* alginate and okra (*Abelmoschus esculentus*) pods extracts on open wound healing process in diabetic mice. *Research Journal of Pharmacy and Technology*. 2020;13(6):2764-2770.
51. An H, Lee JT, Oh SE, Park KM, Hu KS, Kim S, *et al.* Adjunctive hyperbaric oxygen therapy for irradiated rat calvarial defects. *Journal periodontal implant*. 2019;49(1):2-13.
52. Lin PY, Sung PH, Chung SY, Hsu SL, Chung WJ, Sheu JJ, *et al.* Hyperbaric Oxygen Therapy Enhanced Circulating Levels of Endothelial Progenitor Cells and Angiogenesis Biomarkers, Blood Flow, in Ischemic Areas in Patients with Peripheral Arterial Occlusive Disease. *Journal of Clinical Medicine*. 2018;7(12):548.
53. Yamamoto N, Oyaizu T, Enomoto M, Horie M, Yuasa M, Okawa A, *et al.* VEGF and bFGF induction by nitric oxide is associated with hyperbaric oxygen-induced angiogenesis and muscle regeneration. *Scientific Reports*. 2020;10(1):2744.
54. Kuo WT, Shen L, Zuo L, Shashikanth N, Ong MLD, Wu L. Inflammation-induced occludin downregulation limits epithelial apoptosis by suppressing caspase-3 expression. *Gastroenterology*. 2019;157(5):1323-1337.
55. Sangiao NC, Alonso IS, Navas A, Arcos SC, Palencia PF, Careche M, *et al.* Anisakis simplex products impair intestinal epithelial barrier function and occludin and zonula occludens-1 location in differentiated Caco-2 cells. *PLOS Neglected Tropical Diseases*. 2020;14(7):e0008462.
56. Liu X, Liang F, Zhang J, Li Z, Yang J, Kang N. Hyperbaric oxygen treatment improves intestinal barrier function after spinal cord injury in rats. *Frontier in neurology*. 2020;11:563281.

GRAPHICAL ABSTRACT



ABOUT AUTHORS



My name is Mohammad Fathi Ilmawan, a lecturer at Faculty of Medicine, Hang Tuah University, Surabaya, Indonesia. I am currently pursuing a doctoral education at the Faculty of Medicine, Airlangga University. My educational background so far is general medical education, graduating in 1998, and finishing my education as a specialist in internal medicine in 2007. My research experience so far is related to internal medicine, related to chronic kidney failure, hepatopulmonary syndrome, and several tropical infectious diseases. Apart from being a lecturer, the author is also a practicing doctor in a hospital, in the field of internal medicine.

Cite this article: Ilmawan MF, Soetjipto, Suryokusumo MG, Miftahussurur M. Effects of Hyperbaric Oxygen Therapy on the Expression of FGF, MMP-9 and Occludin in the Repair of Gastric Mucosal Erosions. *Pharmacogn J.* 2022;14(3): 660-671.

Effects of Hyperbaric Oxygen Therapy on the Expression of FGF, MMP-9 and Occludin in the Repair of Gastric Mucosal Erosions

ORIGINALITY REPORT

10%
SIMILARITY INDEX

6%
INTERNET SOURCES

7%
PUBLICATIONS

2%
STUDENT PAPERS

PRIMARY SOURCES

1 jkorl.jatsxml.org
Internet Source 1%

2 repository.poltekkes-tjk.ac.id
Internet Source 1%

3 entokey.com
Internet Source 1%

4 Ni Wayan Lisa Suasti, Lunsu Oktafitria, Ellya Aidia, Rahmad Dhani. "The Effect of Active Gambir (Uncaria gambir) Fraction on TNF- α Protein Expression and Lesion Size in Rats Induced Gastritis", Bioscientia Medicina : Journal of Biomedicine and Translational Research, 2018
Publication <1%

5 www.scirp.org
Internet Source <1%

6 Garima Verma, Akranth Marella, Md Shaquiquzzaman, Md Mumtaz Alam. <1%

"Immunoinflammatory responses in gastrointestinal tract injury and recovery.",
Acta Biochimica Polonica, 2013

Publication

7

Submitted to Universitas Brawijaya

Student Paper

<1 %

8

www.medicopublication.com

Internet Source

<1 %

9

Da Hyun Jung, Jun Chul Park, Yong Chan Lee, Sang Kil Lee et al. "Comparison of the Efficacy of Polaprezinc Plus Proton Pump Inhibitor and Rebamipide Plus Proton Pump Inhibitor Treatments for Endoscopic Submucosal Dissection-induced Ulcers", Journal of Clinical Gastroenterology, 2020

Publication

<1 %

10

Wesam Abdel Moneim, Olfat Shaker, Eman Amr. "Effect of non-surgical periodontal treatment on crevicular levels of Chemerin and Fibroblast growth factor 21 in controlled type 2 diabetic and non-diabetic patients both with periodontitis and their glycemic control. A clinical trial", Egyptian Dental Journal, 2019

Publication

<1 %

11

assets.researchsquare.com

Internet Source

<1 %

12

mro.massey.ac.nz

Internet Source

<1 %

13

repository.unair.ac.id

Internet Source

<1 %

14

Submitted to Academy of Family Physicians of Malaysia (AFPM)

Student Paper

<1 %

15

Shudong Zhu, Yan Zhu, Hao Li, Doudou Zhang, Dianzheng Zhang. "The toxic effect of mobile phone radiation on rabbit organs", All Life, 2020

Publication

<1 %

16

eprints.semums.ac.ir

Internet Source

<1 %

17

J. L. Wallace. "Prostaglandins, NSAIDs, and Gastric Mucosal Protection: Why Doesn't the Stomach Digest Itself?", Physiological Reviews, 10/01/2008

Publication

<1 %

18

ijrp.org

Internet Source

<1 %

19

Fransisca Ira Amelia, Muhtarum Yusuf, Artono. "Correlation Between β -Catenin Expression and Staging in Nasopharyngeal Carcinoma Patients", Indian Journal of

<1 %

Otolaryngology and Head & Neck Surgery, 2018

Publication

20

Fadia Rakhmalia, Anik Handayati, Evy Diah Woelansari, Mohd Nazil Salleh. "Analysis of Images of Neutrophil Lymphocyte Ratio and Bacteria Density Level of Helicobacter Pylori in Tissue in Gastritis Patients", International Journal of Advanced Health Science and Technology, 2022

Publication

<1 %

21

gsconlinepress.com

Internet Source

<1 %

22

Guo, M.. "Pre-ischemic exercise reduces matrix metalloproteinase-9 expression and ameliorates blood-brain barrier dysfunction in stroke", Neuroscience, 20080124

Publication

<1 %

23

N. K. Dutta. "In vitro and in vivo efficacies of amlodipine against Listeria monocytogenes", European Journal of Clinical Microbiology & Infectious Diseases, 01/28/2009

Publication

<1 %

24

www.actabiomedica.ru

Internet Source

<1 %

25

Ida Setyaningsih. "Factors Related to Gastritis Events At The Ages 17-21 Years Old in The

<1 %

Work Area of Pesanggrahan Public Health
Center (Puskesmas) in 2018", Muhammadiyah
International Public Health and Medicine
Proceeding, 2021

Publication

26

dx.doi.org

Internet Source

<1 %

27

www.ijop.net

Internet Source

<1 %

28

John A. Mengshol, Matthew P. Vincenti,
Charles I. Coon, Aaron Barchowsky,
Constance E. Brinckerhoff. "Interleukin-1
induction of collagenase 3 (matrix
metalloproteinase 13) gene expression in
chondrocytes requires p38, c-jun N-terminal
kinase, and nuclear factor κ B: Differential
regulation of collagenase 1 and collagenase
3", Arthritis & Rheumatism, 2000

Publication

<1 %

29

Meejung Ahn, RyeoKyeong Koh, Gi Ok Kim,
Taekyun Shin. "Aqueous extract of purple
Bordeaux radish, *Raphanus sativus* L.
ameliorates ethanol-induced gastric injury in
rats", Oriental Pharmacy and Experimental
Medicine, 2013

Publication

<1 %

30

Shimaa M. Elshazly, Dalia M. Abd El Motteleb,
Islam A.A.E-H. Ibrahim. "Hesperidin protects

<1 %

against stress induced gastric ulcer through regulation of peroxisome proliferator activator receptor gamma in diabetic rats", Chemico-Biological Interactions, 2018

Publication

31

Di Xu, Fan Yu, Shangqing Liu, Cai Rong. "Expression of Sortilin in Pancreatic Carcinoma and Influence of Sortilin siRNA Knockdown on Cell Proliferation", Research Square Platform LLC, 2021

Publication

<1%

32

Laura Mäkitalo, Kaija-Leena Kolho, Riitta Karikoski, Hannele Anthoni, Ulpu Saarialho-Kere. "Expression profiles of matrix metalloproteinases and their inhibitors in colonic inflammation related to pediatric inflammatory bowel disease", Scandinavian Journal of Gastroenterology, 2010

Publication

<1%

33

bsdwebstorage.blob.core.windows.net

Internet Source

<1%

34

www.apjr.net

Internet Source

<1%

35

www.clonerresources.com

Internet Source

<1%

36

Anil Kumar Chauhan, Sun Chul Kang. "Therapeutic potential and mechanism of

<1%

thymol action against ethanol-induced gastric mucosal injury in rat model", Alcohol, 2015

Publication

37

Jacqueline Maybin, Hilary Critchley. "Repair and regeneration of the human endometrium", Expert Review of Obstetrics & Gynecology, 2014

Publication

<1 %

38

Pegah Mir Seyed Nazari, Julia Riedl, Ingrid Pabinger, Cihan Ay. "The role of podoplanin in cancer-associated thrombosis", Thrombosis Research, 2018

Publication

<1 %

39

ucanr.edu

Internet Source

<1 %

40

www.jneuroinflammation.com

Internet Source

<1 %

41

www.jourlib.org

Internet Source

<1 %

42

www.nature.com

Internet Source

<1 %

43

Ari R. Joffe, Geoff Brin, Sarah Farrow. "Unreliable Early Neuroprognostication After Severe Carbon Monoxide Poisoning Is Likely Due to Cytopathic Hypoxia: A Case Report and Discussion", Journal of Child Neurology, 2019

<1 %

44

David C. Kluth, Jeremy Hughes. "Chapter 10 Resolution of glomerular inflammation", Springer Science and Business Media LLC, 2008

Publication

<1 %

45

Eric Van Gieson. "Chronic Vasodilation Induces Matrix Metalloproteinase 9 (MMP-9) Expression during Microvascular Remodeling in Rat Skeletal Muscle", Microcirculation, 2/1/2001

Publication

<1 %

Exclude quotes On

Exclude bibliography On

Exclude assignment template On

Exclude matches Off